TRIGGER POINT PAIN FROM THORACOLUMBAR PARASPINAL MUSCLES AS FIRST PRESENTATION OF BODY-TAIL PANCREATIC CANCER DIFFERENTLY ASYMPTOMATIC

Partially reworked english Version of

DOLORE DA TRIGGER POINT DEI MUSCOLI PARASPINALI TORACO-LOMBARI IN CORSO DI CARCINOMA DEL PANCREAS ASINTOMATICO: UN CASO CLINICO.

Published in: Progressi in Reumatologia Clinica 5:13-19 (2011)
Authors: G. Cassisi [1,2] , F. Ceccherelli [2]
Affiliation:
[1] Rheumatology Departmental Unit - Specialist Outpatient Department - ASL 1 Dolomiti - Belluno
[2] A.I.R.A.S. – Italian Association for scientific research and update – Padova

Please address correspondence and reprint request to:
Gianniantonio Cassisi MD
Rheumatology Departmental Unit
Specialist Outpatient Department - AUSL 1 Dolomiti - Belluno - Veneto
Viale Europa 22 – 32100 Belluno
e-mail: cassisi.agordo@libero.it

Spinal pain is very frequent and it represents one of the most common reasons to seek medical advice. Differential diagnosis is an intriguing challenge in which physicians must take particular care to understand the origin of pain and, in particular, to detect severe diseases. For instance, it is known that low back pain can be due to a non-mechanical cause, in 2-4% of cases.
Sometimes spinal pain can originate during visceral diseases such as dysfunctional syndrome or organic lesions, like neoplasms.
However, it is not very common to consider that spinal muscles may provoke pain during patient evaluation in the daily practice. Myofascial pain syndromes and trigger points pain are well known in scientific literature and many contributions have confirmed their overall high prevalence. Some authors verified a prevalence of this nonarticular local musculoskeletal disorder in up to 85% of low back pain. Trigger points may be present during a visceral disease.
This report presents a particular and singular case of a woman with an upper back pain, which started four months before her visit. She presented this symptom as the unique manifestation of a hidden pancreatic cancer.
Only the paraspinal muscle evaluation allowed us to reveal a thoracolumbar trigger point, which was causing persisting pain.
Therefore, we strictly recommend the evaluation of spine muscles in the presence of spinal pain, in order to make a correct differential diagnosis. A trigger point can be the cause of pain itself or can be the sign of an underlying condition, such as a cancer.

Key words

Trigger point, myofascial pain syndrome, pancreatic cancer, lumbar pain, spinal pain

INTRODUCTION

Evaluating spine complaint, physicians rarely consider the muscles as a possible source of pain. The available data actually attribute a prevalence ranging from 30 to 93% to muscle pain, in its different forms; therefore, this is an event far from rare (1,2). We refer in particular to myofascial pain syndromes (MPS), characterized by local and referred pain, which originates from a muscle trigger point (TP). Over 90% of spinal pain is related to mechanical causes (distracting trauma, osteoarthritis, herniated discs, and osteoporosis fractures) (3,4). Nevertheless, physicians should absolutely exclude diseases of non-mechanical origin as possible causes of pain.

On the other hand, there are no reliable data on the prevalence of spine pain due to MPS, although up to 85% prevalence in lumbar pain has been reported in the past (5,6). Many data are instead related to headache and cervical pain with a prevalence that reaches up to 54% (7,8); also chewing disorders can vary from 50 to 90% (9,10).

MPS can be a primary disorder or a secondary event, such as in acute or chronic osteoarticular diseases or visceral pathologies, even of a neoplastic nature (11).

This case report aims to help specialists pay attention to the latter, as well as to improve the knowledge of TP pain, in order to enhance their diagnostic possibilities understanding spine pain of uncertain origin.

Myofascial pain syndrome

MPS or TP myofascial pain (as some authors like to call it today) is a disorder characterized by persistence of a local and referred regional pain from a TP, specific to individual muscle, associated with localized muscle tenderness and moderate functional limitation of movement (12,13). The

typical feature of MPS is the taut band and the related TP inside the band. The pressure on the tender spot is able to cause and reproduce the patient's pain complaint.

No validated criteria are available, nor certain instrumental diagnostic tests, but some highly suggestive information must be taken into consideration from the patient's medical history and visit (Table I). In order to simplify the diagnosis, Gerwin proposed criteria that provide for the presence of a taut palpable band with an exquisite spot tenderness of a nodule in it, the patient's recognition of current pain complaint by pressure of a tender nodule and the painful limit to full stretch range of motion (14). Local twitch response (LTR) and referred pain are additional signs and symptoms, not necessary but strongly suggestive for the diagnosis.

TP is a hyperirritable spot in skeletal muscle that is associated with a hypersensitive palpable nodule in a taut band. The TP is usually localized by palpation of a taut band, a group of tense muscle fibers between the normally relaxed fibers and it corresponds to the mostly painful spot. Normal muscles have no TP, nor taut band.

Taut band and TP examination can be performed with a flat palpation with the fingertips, sliding the skin across muscle fibers to feel the taut band rolling beneath it (Figure 1) or a pincer palpation by picking up the muscle belly between the thumb and fingers, giving the feeling of a cord, a few millimeters in diameter.

Pathognomonic characteristic of MPS clinic is the “local twich-response”, a localized transient contraction of essentially those fibers received in the tense band associated with a TP, usually produced by transverse snapping palpation or by needle penetration. It may be seen as a twitch or dimpling of the skin, near the attachments or palpated through the skin with the examining hand. (12,15).

CASE REPORT

P.G., a 57 year old woman, came to our observation for low back pain, persisting for about 4 months, with a suspected inflammatory rheumatism, on February 2019.

The lumbar pain was initially localised on the left side of the dorsal-lumbar passage. Then it spread over time to neighboring areas with a band distribution, but with no referred pain. The pain was persistent and not influenced by any position of the body, nor by movement or rest, only moderately highlighted by horizontal and seated positions. From the beginning, she never presented functional limitations, not even when she woke up. Nausea and vomiting were present during pain exacerbations; initially NSAID response was good.

Autoimmune thyroiditis with normal TSH, primary hand osteoarthritis and dyslipidemia were reported in the remote pathological history; a previous occasional increase in alanine-amino-transferase and gamma-glutamyl-transferase was also reported. There was nothing to highlight in the family and physiological history.

The general and joint physical examination were normal. The muscle examination in the painful area showed to the left of the vertebral spinous apophysis line, at the dorsal-lumbar passage, a soft, rounded, well-palpable nodule, referable to a TP of the thoraco-lumbar paraspinal muscles, probably at the deep group (multifidus?) (Figure 2). The digital pressure of the nodule evoked a LTR.

The patient already carried out instrumental exams that showed a slight vertebral scoliosis and a straightness of the lumbar tract on an X-ray of the spine and a slight L4-L5-S1 discopathy at a MRI, with minimal and not significant bulging. An abdomen US scan was normal in November 2018.

Blood tests pointed out only a modest increase in ESR first hour (30mm/hour) and a higher level of CRP (1.34 mg/dl); a modest increase in blood glucose and gamma-glutamyl-transferase were present; aminotransferase and alkaline phosphatases were normal; thyroid hormone values were normal with a T4 at the lower limits of the range. Antinuclear, anti-nDNA, anti-thyroid, anti-HCV antibodies were negative; anti-Hbs antibodies were positive.

We decided for a prompt trigger point injection with a 2 ml solution of Lidocaine Hydrochloride 2% and 3 ml of physiological saline solution, according to the usual techniques (12.16). The patient obtained an immediate resolution of her pain.

The rise of the inflammation values, however, suggested a deeper investigation with a bone scan, in order to exclude a possible spondylarthropathy, and a verification of the low-back pain in a short time.

A week later, she reported a low back pain relapse after about 3 days from the TP injection and a better relief for the pain from nimesulide than acetaminophen plus codeine at home. Kinesiotherapy and spinal massage had instead worsened the pain. A further evaluation of the inflammatory value presented a considerable increase in ESR first hour (83mm/hour) and in CRP (3.37mg/dl).

New anamnestic elements revealed that she had lost her appetite and about 4Kg of weight for about a month, even if the patient connected this problem to her anxious state, relative to pain.

A new abdominal US scan showed a huge pancreatic mass accompanied by a liver localization, likely as a secondariety. Subsequent investigations in hospitalization led to the diagnosis of carcinoma of the body and the neck of the pancreas, already metastasized.

After a few months the patient died because of the rapid cancer evolution.

DISCUSSION

Spine pain, but especially low back pain, is the second most frequent reason for a visit to a doctor, with a mean prevalence per year of about 30% (17,18).

Low back pain can arise from different spinal structures and in different pathological conditions, but there is no evidence that instrumental diagnostics can always reveal the origin of pain (19,20). Most of the low back pain resolves spontaneously, already 60% within 6 weeks and up to 80-90% in 12 weeks (17).

Distinguishing lower back pain of mechanical or inflammatory origin is very important, but taking into account their respective prevalence is needed: mechanical pain represents, in fact, more than 90% of low back pain causes and up to 97% in patients assessed in the general practitioner office, under 65 years old. Only 1% of low-back pain is of non-mechanical origin and 2% is due to visceral diseases (3,4). Persistent pain should not be underestimated especially if present at night and when it is

unaffected by movement or different postures. The exclusion of the most severe causes is essential for correct management of a patient with spine pain.

Our clinical report highlights the possibility that an aggressive visceral disease may initially occur only with spine pain. This kind of pain was quite different from the typical pain of pancreatic diseases and clearly neither referred by it and nor segmental.

In this event, the pain was certainly referable to the palpable nodule of the thoraco-lumbar muscles, a TP secondary to the pancreatic cancer. TP pain, on the other hand, has analogies with the phenomenon of true parietalisation of pain. This kind of pain associates with a local decrease in the pain threshold, due to central sensitization phenomena, with skin and/or muscle hyperalgesia (21,22,23).

The rapid response to the TP injection confirmed the muscle origin of the pain, but its rapid recurrence signified a wake-up call in the clinical evaluation, which allowed the highlighting of the related cause of spine pain.

In fact, the treatment of TP has always a diagnostic and therapeutic hand-in-hand value. If the pain really originates from it, the anesthetic injection allows us to check its disappearance in a few minutes. Nevertheless, taut band and TP injection is one of the most effective treatments of MPS (24,25), inactivating the TP by inducing a blockage of the feed-back mechanisms of the taut band. The mechanical disruption of the myocytes membrane causes a variation of the intra- and extra-cellular balance of Calcium and Potassium ions, established after the muscle contraction. On the other hand, the injected solution would reduce the concentration of irritant catabolites. Anesthetics would also increase the microcirculation in the TP due to its vasodilating action (Lidocaine or Procaine) (12,26). TP Injection is also used in cancer patients (27).

Two particular features are peculiar to this case report: the pain, as the unique symptom that characterized the silent onset of the pancreatic cancer, and its origin, not directly due to the cancer but to the TP.

We have not found similar scientific contributions in the literature. Actually, some authors recently recommended the evaluation of myofascial pain in routine clinical examination of cancer patients suffering from pain (28).

Some clinical data were ambiguous, highlighting the need for greater attention to low back pain of undefined origin and/or rebellious to the treatment. Certain elements led to a diagnostic delay. Among these, surely the absence of symptoms other than pain, the normal ultrasound examination (moreover promptly performed about 3 months before), the absence of significant blood test changes, and, later, the attribution of the loss of weight to the reactive anxious state. Lastly, the finding of an inflammatory test increase (which probably recommended a rheumatologic consultation) might suggest an inflammatory event, rather than a cancer, although Ves and Pcr may be higher in this serious disease.

Some data actually provoked a wake-up call. In particular, the characteristics of patient pain: duration (four months), persistence (even at night), unusual location (dorso-lumbar transition), no functional limitation of the spine (not even in the morning), independence of spine movement or posture, and, finally, no benefit from kinesiotherapy and local physical therapies. Lastly, particular attention was paid to the loss of 4 kg in a month.

Some of these elements are part of the red flags of low-back pain (Table II), thus reinforcing the belief that particular attention is due also to those little clinical data capable of pointing out the potential seriousness of a spine pain.

CONCLUSIONS

Spine pain represents one of the most frequent reason for a medical consultation. Physicians are often called to differentiate its origin. During the clinical evaluation, signs suggestive of inflammatory or mechanical diseases must be taken into careful consideration, but without neglecting other origins.

We therefore recommend a cautious examination of the paraspinal muscle group in order to improve the diagnosis, especially when difficult.

The finding of tense muscles, taut band or TP may give reason for otherwise unexplained spine pains, often in the case of the typical kit of negative blood tests and instrumental investigations, often useless for the diagnosis. In these cases, the injection of TP had both diagnostic and therapeutic utility.

REFERENCES

1. SKOOTSKY SA, JAEGER B, OYE RK. Prevalence of myofascial pain in general internal medicine practice. West J Med 1989; 151: 157-100.
2. GERWIN RD. A study of 96 subjects examined both for fibromyalgia and myofascial pain. J Musculoske Pain 1995; 3(Suppl.1): 121(abs).
3. DEYO RA, WEINSTEIN JN. Low back pain. N Engl J Med 2001; 344: 363-370.
4. COHEN SP, ARGOFF CE, CARRAGEE EJ. Management of low back pain. BMJ 2008; 337: a2718.
5. SIMONS DJ. Examining for myofascial trigger points. Arch Phys Med Rehabil 1993; 74: 676-7.
6. MALANGA GA, CRUZ COLON EJ. Myofascial low back pain: a review. Phys Med Rehabil Clin N Am 2010; 21: 711-24.
7. FISHBAIN DA, GOLDBERG M, STEELE R, ROSOMOFF H. DSM-III diagnoses of patients with myofascial pain syndrome (fibrositis). Arch Phys Med Rehabil 1989; 70: 433-8.
8. FRICTON JR, KROENING R, HALEY D, SIEGERT R. Myofascial pain syndrome of the head and neck: a review of clinical characteristics of 164 patients. Oral Surg Oral Med Oral Pathol 1985; 60: 615-23.

9. SCHIFFMAN EL, FRICTON JR, HALEY DP, SHAPIRO BL. The prevalence and treatment needs of subjects with temporomandibular disorders. J Am Dent Assoc 1990; 120: 295-303.
10. FOREMAN PA. The changing focus of chronic temporomandibular disorders: management within a hospital-based, multidisciplinary pain centre. N Z Dent J 1998; 94: 23-31.
11. CASSISI G. Le sindromi dolorose miofasciali. Ger Extraosp 2016; 11(3); 9-22.
12. SIMONS DG, TRAVELL JG, SIMONS LS. Myofascial pain and disfunction: the trigger point manual, vol. 1. 2nd ed. Baltimore: Williams and Wilkins, 1999.
13. FRICTON JF. Myofascial Pain: Clinical characteristic and diagnostic criteria. Proceedings from the 2th World Congress on Myofascial Pain and Fibromyalgia. J Musculoske Pain 1993; 3/4: 37-47.
14. GERWIN R, FRICTON J. Myofascial pain syndrome: Workshop Sessions. Myopain 2004: The International Myopain Society; 6th International Scientific and Clinical Meeting. July 22, 2004, Munich, Germany.
15. RACHLIN ES. History and physical examination for myofascial pain syndrome. In: Rachlin ES, Rachlin IS, editors. Myofascial pain and fibromyalgia, 2nd ed. St. Louis: Mosby, 2002: 217-230.
16. RACHLIN ES, RACHLIN IS. Trigger point management. In: Rachlin ES, Rachlin IS, editors. Myofascial pain and fibromyalgia, 2nd ed. St. Louis: Mosby, 2002: 234-251.
17. ANDERSSON GBJ. Epidemiological features of chronic low-back pain. Lancet 1999; 354: 581-5.
18. ANDERSSON GBJ. The epidemiology of spinal disorder. In: Frymoyer JW, editors. The Adult Spine: Principles and practice. New York: Raven Press, 1997: 93-141.
19. WHEELER AH, MURREY DB. Spinal pain: pathogenesis, evolutionary mechanism, and management. In: Pappagallo M, editors. The Neurological Basis of Pain. New York: McGraw-Hill, 2005: 421-452.

20. VAN TULDER MW, ASSENDELFT WJ, KOES BW, BOUTER LM. Spinal radiographic findings and nonspecific low back pain. A systematic review of observational studies. Spine 1997; 22: 427-34.
21. GIAMBERARDINO MA. Recent and forgotten aspects of visceral pain. Eur J Pain 1999; 3: 77-92.
22. GIAMBERARDINO MA, AFFAITATI G, FABRIZIO A, COSTANTINI R. Myofascial pain syndromes and their evaluation. Best Pract Res Clin Rheumatol 2011;25(2):185-98.
23. CASSISI G, SARZI-PUTTINI P, CASALE R, ET AL. Pain in fibromyalgia and related conditions. Reumatismo. 2014;66:72-86
24. HONG CZ. Myofascial pain therapy. J Musculoske Pain 2004; 3/4: 37-43
25. DESAI MJ, SAINI V, SAINI S. Myofascial Pain Syndrome: A Treatment Review. Pain Ther 2013;2: 21-36
26. GERWIN RD, DOMMERHOLT PT, SHAH JP. An expansion of Simons' integrated hypothesis of trigger point formation. Curr Pain Headache Rep 2004; 8: 468-75.
27. HASUO H, KANBARA K, ABE T, SAKUMA H, FUKUNAGA M.J. Factors associated with the Efficacy of Trigger Point Injection in Advanced Cancer Patients. Palliat Med 2017;20:1085-1090.
28. KALICHMAN L, MENAHEM I, TREGER I. Myofascial component of cancer pain review. J Bodyw Mov Ther 2019;23:311-315.
29. WHEELER AH. Diagnosis and management of low back pain and sciatica. Am Fam Physician 1995; 552; 133-141.

TABLES AND LEGENDS

TABLE I - Anamnestic and clinical features of MPS (12)

• A history of sudden onset during or shortly following acute overload stress, or a history of gradual onset with chronic overload of affected muscle
• Characteristic patterns of pain that are referred from TP, specific to individual muscle
• Weakness and restriction in the stretch range of motion of the affected muscle
• A taut palpable band in the affected muscle
• Exquisite, focal tenderness to digital pressure in the band of taut muscle fibers
• A local twitch response elicited through snapping palpation or needling of the tender spot
• The reproduction of the patient's pain complaint by pressure on, or needling of, the tender spot
• The elimination of symptoms by therapy directed specifically to the affected muscles

TABLE II - RED FLAGS for spinal pain
Simplified and modified from Wheeler AH (29)

- systemic symptoms: fever, fatigue, weight loss
- non-mechanical persistent pain, especially on the dorsal back
- pain associated with visceral function
- severe morning stiffness
- previous cancers, tuberculosis, use of steroids
- signs of wide neurological impairment
- old age
- inability to walk, to care for themselves, to work
- request for narcotic analgesics or psychoactive drugs
- deformity of vertebral structure on x-rays

TAKE HOME MESSAGE

• Myofascial TP pain is frequent, although largely underestimated, and it can be easily identified
• The typical feature of MPS is the taut band and the related TP inside the band
• The TP pain can mimic other diseases or it can be secondary to them
• The injection of PT has diagnostic and therapeutic value
• A careful examination of the paraspinal muscles is recommended, evaluating spine pain
• Red flags for spinal pain should always be considered

FIGURES

FIGURE 1

Thoracolumbar taut band and TP examination performed with flat palpation with the fingertips



FIGURE 2

Deep thoracolumbar paraspinal muscles: the multifidi, possible TP site in the case report
(from Simons DG et al - 12)

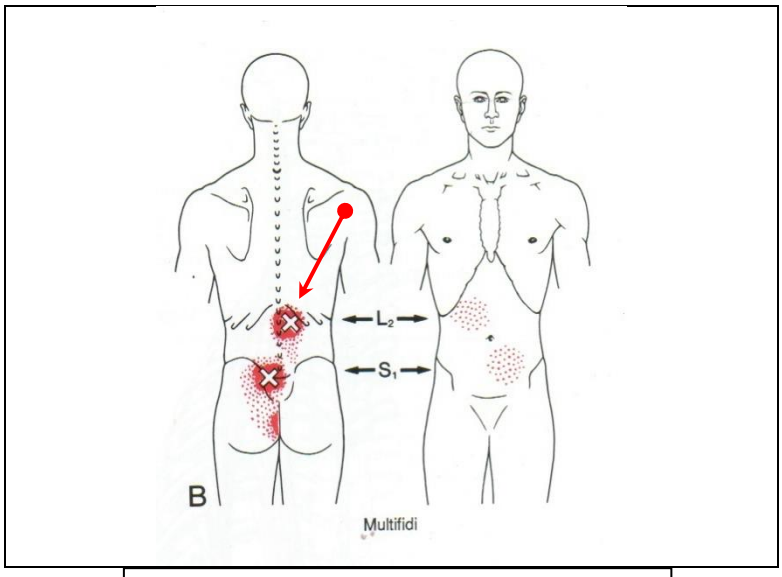

Trigger points and their referred pain